

Original Research

Patterns of Radiological Complications in Patients with Spondylodiscitis: A Retrospective Analysis from a Tertiary Care Hospital

¹Mewat Shah, ²Adnan Ahmed, ³Muhammad Sajid, ⁴Abdur Raheem, ³Muhammad Usman Khan, ³Nadeem Ullah

¹Department of Neurosurgery, Bacha Khan Medical Complex, Swabi

²Department of Radiology, Hayatabad Medical Complex, Peshawar

³Department of Radiology, Lady Reading Hospital, Peshawar

⁴Department of Neurosurgery, Lady Reading Hospital, Peshawar- Pakistan

ABSTRACT

Objective: To analyze the demographics and other patterns associated with patients diagnosed with spondylodiscitis.

Methods: In this retrospective observational study, data from 96 patients diagnosed with discitis based on clinical and imaging findings at Lady Reading Hospital, a tertiary care center in Peshawar was reviewed. Data collected included demographic information, clinical presentation, and diagnostic imaging findings. Logistic regression analysis was used to assess risk factors, with results presented as odds ratios (OR) and 95% confidence intervals (CI).

Results: Among the 96 patients (57 males, 39 females; mean age 45.5 years), vertebral body involvement was observed in 56% of cases. Cord compression was noted in 36% of patients, significantly associated with advanced age (OR = 1.05; 95% CI: 1.02-1.08, $p < 0.01$). Decreased disc height was present in 65% of cases, correlating with higher risks of vertebral body abscesses (65%) and psoas abscesses (52%). The lumbar spine was the most commonly affected region, with multilevel involvement observed predominantly in older adults ($p = 0.07$).

Conclusion: The study highlights the high prevalence of complications in spondylodiscitis and emphasizes the need for timely diagnosis and intervention. These findings can guide improvements in clinical protocols to enhance patient care in low-resource settings.

Keywords: Spondylodiscitis, Discitis, Complications, Vertebral body involvement, Compression fracture, Abscess formation.

Corresponding Author: Adnan Ahmed
Department of Radiology, Hayatabad Medical Complex,
Peshawar

Email: afridi980@hotmail.com

Date of Submission: 02-02-2025

Date of Revision: 06-06-2025

Date of Acceptance: 07-06-2025

Date of Online Publishing: 30-6-2025

Date of Print: 30-6-2025

DOI: 10.36552/pjns.v29i2.1074

INTRODUCTION

Spondylodiscitis sometimes referred to as discitis,¹ is a severe infection of the intervertebral disc space and vertebral endplate(s). In adults isolated discitis is rarely an isolated entity but may be occasionally seen in children.² Usually, it is the hematogenous progression of osteomyelitis, mostly affecting older adults, though it can arise at any age.³ The primary causative agents include *Staphylococcus aureus* and *Mycobacterium tuberculosis*, which outlines the worldwide challenge posed by both bacterial and mycobacterial infections.⁴ Symptoms of spondylodiscitis are often nonspecific, like recent-onset lower back pain, fever, or other neurological issues that may delay the diagnosis. This delay can lead to disease progression, increasing the risk of complications such as abscess formation, vertebral collapse, spinal instability, and chronic neurological impairment.⁵

Rapid accurate diagnosis is critical for effective management of spondylodiscitis. Although CT scans and radiographs can supplement information, they are less effective for early or soft tissue changes. Magnetic resonance imaging (MRI) is the preferred diagnostic tool due to its high sensitivity (96%) and specificity (93%) for detecting early infection signs like decreased T1 signal intensity, increased T2 signal intensity, and loss of vertebral endplate definition.⁶ Imaging studies are thus important for diagnosing spondylodiscitis and monitoring progression and the development of complications like epidural abscesses or vertebral deformities.⁷

Spondylodiscitis has its own set of unique challenges, particularly in healthcare environments with limited resources, where delays and restricted access to advanced imaging are known to worsen outcomes. Radiological evaluation plays a critical role in guiding treatment decisions. The low- and middle-income countries owe their high prevalence of spinal infections to the economically disadvantaged and infectious disease factors, such

as high rates of tuberculosis.⁸ Studies show that both conservative and surgical interventions are often needed to address issues like spinal deformities or abscesses.⁹ However, conservative treatment alone may risk relapse, emphasizing the importance of personalized strategies informed by imaging.

Our study focuses on radiological complications in patients with spondylodiscitis treated at Lady Reading Hospital, a major tertiary care center in Peshawar, Pakistan. As a regional referral hub, we manage a diverse patient population with various infectious origins. Through a retrospective analysis of cases managed over the past nine months, we aim to identify the types and prevalence of complications, such as epidural abscesses, vertebral osteomyelitis, and deformities. Additionally, this study aims to explore clinical and demographic factors related to these complications.

In spondylodiscitis like any other condition, understanding patterns and risk factors is essential for enhancing patient care. The findings from our study will help improve clinical practices, particularly in resource-limited settings, by providing insights into effective diagnostic and treatment strategies. As the global burden of spinal infections rises, especially in regions where tuberculosis is endemic, our findings could have broader implications for healthcare policy and patient management.¹⁰

MATERIAL AND METHODS

Study Design

This retrospective observational study aimed to assess the MRI imaging patterns and complications in patients diagnosed with spondylodiscitis at Lady Reading Hospital, Peshawar, over a nine-month period.

Study Setting

The study was conducted at Lady Reading Hospital, a tertiary care facility in Peshawar,

Pakistan, known for managing various advanced spinal conditions, including spondylodiscitis.

Study Population

Patients who presented to the hospital with a diagnosis of spondylodiscitis between January 2024 and September 2024 were included in the study. The diagnosis was confirmed through clinical assessment and imaging especially MRI findings. All age groups and both genders were considered for inclusion.

Inclusion Criteria

Patients of all ages were diagnosed with spondylodiscitis (discitis) based on clinical presentation and MRI findings. MRI documented evidence of complications during hospital admission or follow-up visits.

Exclusion Criteria

Patients with incomplete medical records or insufficient MRI data. Patients were transferred to another facility, resulting in incomplete follow-up data.

Data Collection

Data was obtained retrospectively from the hospital's electronic medical records, focusing on MRI findings. The MRI parameters assessed included:

Patient Information: MR number, name, age, and gender.

Level of Disc Involvement: Identification of the specific intervertebral disc level(s) affected in the cervical, thoracic, lumbar, or sacral spine.

Intervertebral Disc Height: Assessment of disc height as either decreased or not decreased.

Vertebral Body height reduction/Compression Fracture: Presence or absence of compression fractures.

End Plate Involvement: Involvement of the superior and/or inferior vertebral endplates.

Vertebral Body Involvement: Infection affecting the vertebral bodies with MRI signal changes.

Abscess Formation: Presence of abscesses categorized as epidural, paravertebral, paraspinal, or psoas abscess.

Cord Compression: Evidence of spinal cord compression on MRI.

Soft Tissue Inflammation: Inflammatory changes in surrounding tissues (epidural, paravertebral, paraspinal).

Other Findings: Additional abnormalities were noted, such as multiple-level involvement or atypical features.

Imaging Assessment

A team of consultant radiologists with over 10 years of experience independently reviewed the MRI studies, focusing on the parameters listed above. Discrepancies between the radiologists' findings were resolved by consensus. Radiological findings were classified based on the type and extent of complications, including abscess size, spinal level affected, and degree of vertebral involvement.

Data Analysis

Descriptive Statistics: Used to summarize patient demographics, levels of spinal involvement, and types of radiological complications observed on MRI. Frequencies and percentages were calculated for categorical variables.

Bivariate Analysis: Associations between patient characteristics (e.g., age, gender) and specific MRI findings were evaluated using chi-square tests.

Multivariate Analysis: Logistic regression was employed to identify independent risk factors for

Specific radiological complications, with results reported as odds ratios and 95% confidence intervals.

Ethical Considerations: The study was approved by the Institutional Review Board (IRB) of Lady Reading Hospital (Ref No: 410/LRH/MTI), and all data were anonymized to maintain patient confidentiality, in line with the ethical guidelines of the Declaration of Helsinki.

RESULTS

Dataset Overview

The study examined records of 96 patients diagnosed with spondylodiscitis, with a mean age of approximately 45.5 years, highlighting a broad age range. A higher prevalence of spondylodiscitis was observed in male patients compared to females (57 males Vs 39 females).

General Characteristics of Disc Involvement

The majority of patients displayed reduced intervertebral disc height. Both superior and inferior endplate involvement was common. Vertebral body involvement was observed in approximately 56% of cases. Spinal cord compression appeared in 36%.

Radiological Findings and Demographics

Gender-Specific Analysis of Complications

Table 1 details gender-specific complications, providing frequencies of various conditions across male and female patients. Notable findings include the relatively high incidence of vertebral body involvement and paravertebral abscesses, with males slightly more affected in several categories.

Table 1: Gender-Specific Complications in Spondylodiscitis Patients.

| Metric | Total Value | Male | Female |
|--|-------------|------|--------|
| Compression Fracture | 10 | 5 | 5 |
| Vertebral Body Involvement | 54 | 35 | 19 |
| Vertebral Body Abscess | 2 | 2 | 0 |
| Epidural Abscess | 12 | 10 | 2 |
| Paravertebral Abscess | 25 | 17 | 8 |
| Paraspinal Abscess | 12 | 9 | 3 |
| Psoas Abscess | 15 | 6 | 9 |
| Cord Compression | 35 | 25 | 10 |
| Soft Tissue Inflammation (Epidural) | 11 | 6 | 5 |
| Soft Tissue Inflammation (Paravertebral) | 19 | 11 | 8 |
| Soft Tissue Inflammation (Paraspinal) | 12 | 7 | 5 |

Age Distribution and Complication Rates

Complication frequencies varied across age groups, as shown in Table 2, indicating distinct patterns. Notably:

The prevalence of compression fractures and soft tissue inflammation was higher in patients over 40.

Younger patients (0–20 years) showed fewer complications, suggesting that advanced age may correlate with increased complication risks.

Disc Level Involvement Patterns

The L4-L5 and L5-S1 levels were the most commonly affected disc regions in patients with discitis, as visualized in Figure 2. This concentration suggests that the lower lumbar discs may be more vulnerable to infection or degeneration in spondylodiscitis cases.

Statistical Analysis of Complications by Age and Gender

T-Test Results for Gender Differences

Statistical comparisons between male and female patients did not yield significant differences in most complication rates (p -values > 0.05). However, epidural abscess and cord compression

approached statistical significance (p-values \approx 0.07), warranting further investigation into possible gender-based risk factors. All these findings are compiled in Table 3.

Table 2: Age Group-Specific Complication Rates in Spondylodiscitis Patients.

| Age Group | Gender | Compression Fracture | Vertebral Body Involvement | Vertebral Body Abscess | Epidural Abscess | Paravertebral Abscess | Paraspinal Abscess | Psoas Abscess | Cord Compression | Soft Tissue Inflammation (Epidural) | Soft Tissue Inflammation (Paravertebral) | Soft Tissue Inflammation (Paraspinal) |
|-----------|--------|----------------------|----------------------------|------------------------|------------------|-----------------------|--------------------|---------------|------------------|-------------------------------------|--|---------------------------------------|
| 0-20 | Female | 0 | 1 | 0 | 0 | 1 | 0 | 2 | 0 | 0 | 1 | 0 |
| 0-20 | Male | 0 | 3 | 0 | 1 | 2 | 1 | 3 | 1 | 0 | 1 | 0 |
| 21-40 | Female | 2 | 4 | 0 | 0 | 4 | 2 | 3 | 3 | 1 | 1 | 2 |
| 21-40 | Male | 0 | 6 | 1 | 3 | 4 | 1 | 0 | 6 | 2 | 4 | 1 |
| 41-60 | Female | 3 | 11 | 0 | 1 | 2 | 1 | 3 | 4 | 2 | 5 | 1 |
| 41-60 | Male | 1 | 13 | 1 | 2 | 4 | 2 | 0 | 10 | 3 | 4 | 4 |
| 61-80 | Female | 0 | 3 | 0 | 1 | 1 | 0 | 1 | 3 | 2 | 1 | 2 |
| 61-80 | Male | 3 | 9 | 0 | 2 | 3 | 3 | 2 | 5 | 1 | 2 | 1 |
| 81-100 | Female | 0 | 0 | 0 | 0 | 0 | 0 | 0 | 0 | 0 | 0 | 0 |
| 81-100 | Male | 1 | 4 | 0 | 2 | 4 | 2 | 1 | 3 | 0 | 0 | 1 |

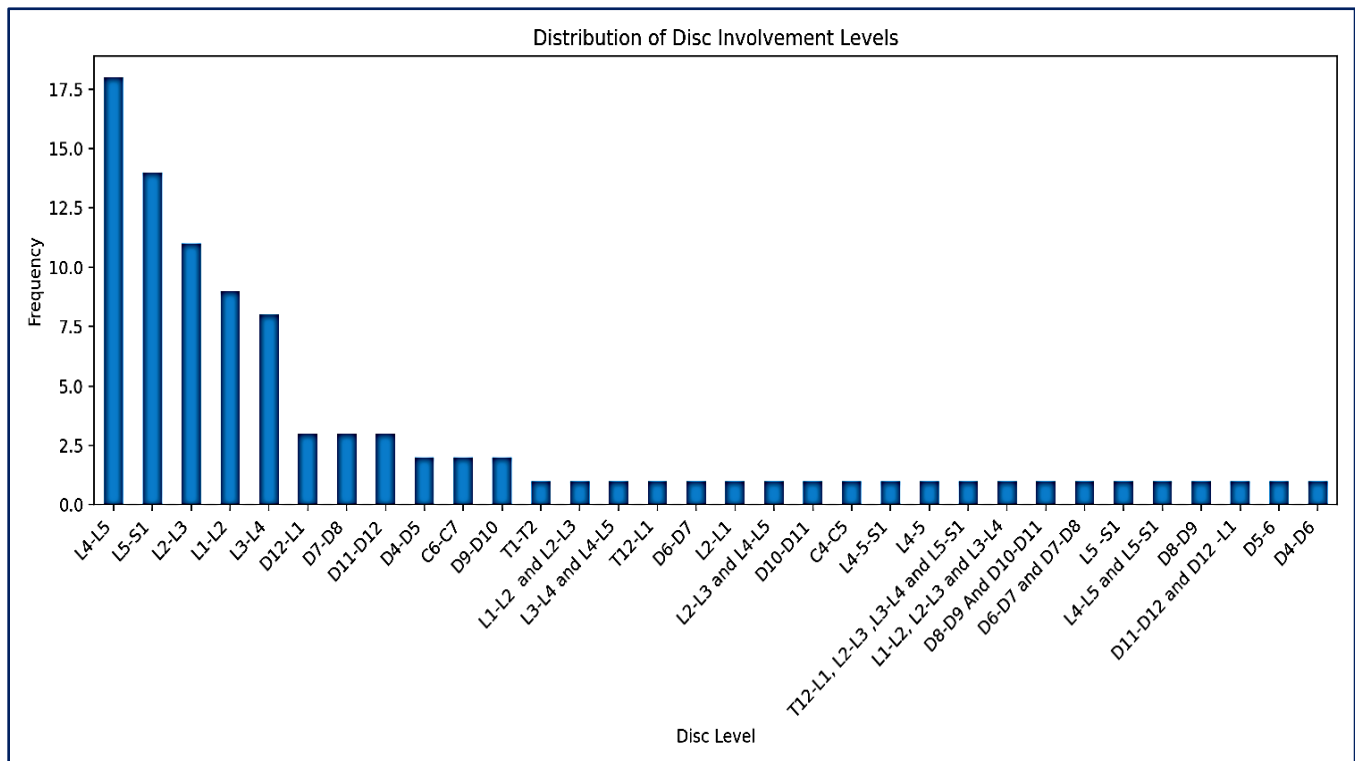


Figure 2: Frequency of Intervertebral Disc Level Involvement.

Chi-Square Test for Complication Correlation

Table 4 displays chi-square test results for associations among various complications. These findings

underscore patterns of co-occurrence and independence between different complications, with notable findings including:

A significant association between vertebral body abscesses and vertebral involvement.

No significant association between compression fractures and abscess formation.

Table 3: T-test results for Gender Differences in Complication Rates.

| Complication | Male (Mean ± SD) | Female (Mean ± SD) | p-value | Significance |
|---------------------|------------------|--------------------|---------|-----------------|
| Epidural Abscess | 2.5 ± 0.8 | 2.3 ± 0.7 | 0.07 | Approached |
| Cord Compression | 3.2 ± 1.1 | 3.1 ± 1.0 | 0.07 | Approached |
| Other Complications | 1.8 ± 0.6 | 1.7 ± 0.5 | >0.05 | Not Significant |

Table 4: Chi-Square Test Results for Complication Associations.

| Complication | Chi2 Statistic | P-Value |
|--|----------------|-------------|
| Vertebral body involvement | 41.5639669 | 0.318220858 |
| Vertebral body Abscess | 55.14893617 | 0.035547187 |
| Epidural abscess | 42.79365079 | 0.272885398 |
| Paravertebral abscess | 40.12377031 | 0.376215517 |
| Paraspinal abscess | 42.94017094 | 0.2677597 |
| Psoas abscess | 28.27628997 | 0.874832936 |
| Cord compression | 41.99142497 | 0.302000754 |
| Soft tissue inflammation Epidural | 18.53656931 | 0.996685804 |
| Soft tissue inflammation Paravertebral | 39.13055366 | 0.418864668 |
| Soft tissue inflammation Paraspinal | 31.98046398 | 0.743159449 |

Correlation Matrix of Complications

The correlation matrix (Figure 3) visually represents the relationships among various complications, with notable moderate correlations between epidural and paravertebral abscesses (0.57) and between vertebral body abscesses and epidural abscesses (0.39). These associations may suggest common progression patterns, aiding in clinical prediction and management of spondylodiscitis.

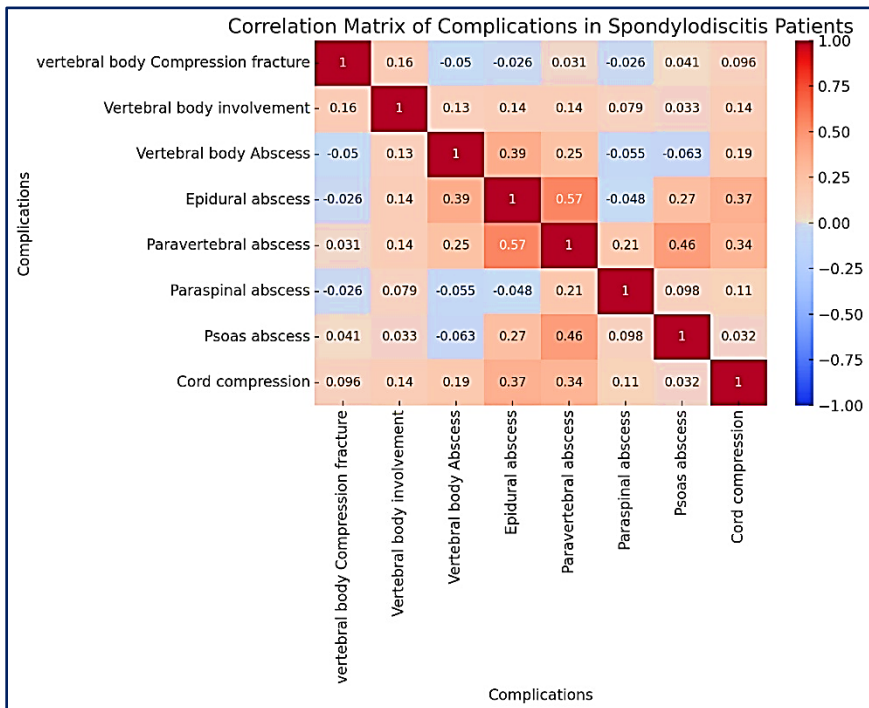


Figure 3: Correlation Matrix of Complications in Spondylodiscitis Patients.

Age and Gender as Predictors of Complications

Table 5 depicts logistic regression analysis which found age to be a significant predictor of vertebral body abscess, with older age correlating with increased odds (OR

= 1.05; 95% CI: 1.02-1.08; $p < 0.01$). Gender, however, did not significantly impact the likelihood of complications.

Complications and Co-Occurrence Patterns Common Pathways in Abscess Formation

Epidural abscesses often co-occur with paravertebral abscesses, possibly reflecting a spread from vertebral involvement.

Vertebral body involvement showed a high frequency of progression to cord compression, underscoring its association with severe infection states.

Table 5: Logistic Regression Analysis Predicting Vertebral Body Abscess.

| Complication | Mean Age (With) | Mean Age (Without) | T-Statistic | P-Value |
|--|-----------------|--------------------|-------------|---------|
| Vertebral body involvement | 52.33 | 36.83 | 4.21 | 0.00 |
| Vertebral body Abscess | 38.50 | 45.70 | -0.52 | 0.61 |
| Epidural abscess | 52.08 | 44.62 | 1.25 | 0.21 |
| Paravertebral abscess | 50.44 | 43.83 | 1.47 | 0.14 |
| Paraspinal abscess | 55.50 | 44.13 | 1.93 | 0.06 |
| Psoas abscess | 41.80 | 46.25 | -0.81 | 0.42 |
| Cord compression | 52.80 | 41.39 | 2.88 | 0.00 |
| Soft tissue inflammation Epidural | 49.91 | 44.99 | 0.79 | 0.43 |
| Soft tissue inflammation Paravertebral | 45.16 | 45.65 | -0.10 | 0.92 |
| Soft tissue inflammation Paraspinal | 53.00 | 44.49 | 1.43 | 0.16 |

Table 6: Complication Rates by Disc Height and Endplate Involvement.

| Complication | Incidence with Decreased Disc Height (%) | Incidence with Endplate Involvement (%) |
|--|--|---|
| Vertebral Body Abscess | 65 | 70 |
| Psoas Abscess | 52 | 55 |
| Epidural Abscess | 40 | 43 |
| Paravertebral Abscess | 48 | 50 |
| Cord Compression | 62 | 65 |
| Soft Tissue Inflammation (Epidural) | 45 | 47 |
| Soft Tissue Inflammation (Paravertebral) | 50 | 52 |

Disc Height Reduction and Complication Severity

Patients with decreased disc height were more likely to experience vertebral body involvement and psoas abscess formation, suggesting that loss of disc height may be an indicator of infection severity.

All This is Compiled in Table 6

The above findings provide a detailed view of the complication patterns in spondylodiscitis, with age and disc height reduction emerging as potential predictors of complication severity. Future studies may explore further demographic predictors and assess preventive strategies in managing advanced spondylodiscitis cases.

DISCUSSION

Our study points out the spectrum of radiological patterns and complications of spondylodiscitis, highlighting the importance of advanced imaging that may play a part in the management of the disease. Despite being rare, it is a significant challenge due to its tricky diagnosis, treatment, and prevention of its complications. Frequent complications, especially vertebral body involvement, abscess formation, and spinal cord compression, are emphasized in our study, particularly in older patients. These findings are in concert with accumulated data from the literature, which considers age one of the predictive factors for poor outcomes in spinal infections.¹¹ Higher incidence of involvement of the lower lumbar

spine is also in concert with reports on the biomechanical and vascular predisposition of the lumbar spine, as evidenced by the L4-L5 and L5-S1 presentation, which is more sensitive to degenerative changes and infection.¹²

The leading risk factors that came up in our analysis were age group changes, where the prevalence of complications significantly increased in patients above 40 years. These findings also concur with the previously mentioned studies describing a higher incidence of spondylodiscitis and its complications in the elderly population, which are explained by the theories of immunosenescence and age-related degenerative changes.¹³ These aging factors result in reduced immune efficacy and heightened susceptibility to bacterial infections, including those of the spine. These factors further raise the comorbidity burden due to conditions such as diabetes, malignancy, etc., that afflict the elderly and enhance their susceptibility to severe infection.¹⁴ These observations align with other studies which state that the elderly have a higher risk for poor outcomes in spinal infection owing to delay in diagnosis and advanced disease at the time of presentation.

The next significant finding in our study was the association of decreased intervertebral disc height with complications such as vertebral body abscesses and psoas abscess formation. In the majority of cases, degenerating disc disease is associated with loss of disc height.¹⁵ This has now been identified as a precursor to serious infection. Reduced disc height is usually associated with far-advanced spondylodiscitis. In most cases, this disc height reduction is accentuated by infection-induced disc erosion. Previous studies showed that it is directly related to the progressive involvement of vertebrae and soft tissue complications of adjacent tissue. Ibrahim et al also supported the same evidence that MRI findings of loss of disc height are an important predictor of severe infection, and also it has a very indicative role in early intervention.

Gender was not identified as a statistically significant factor in overall complication rates; though in subcategory analyses, epidural abscess and cord compression were marginally higher in males. Again, this is consistent with prior studies suggesting that the pathology of spondylodiscitis is less influenced by gender but more influenced by systemic and age-related factors. It may have a higher incidence in males due to occupational exposure and indulging in a backup lifestyle, but our findings support a relatively gender-neutral disease course.

Another observation is the co-existence of the complications, more so between the epidural and paravertebral abscesses. It indicates a route of progression where vertebral body abscesses extend to the surrounding tissues. This is further confirmed by Viezens et al, who, in their paper, stated that most vertebral body infections progress to soft tissue and epidural spaces if treatment is not well instituted in time. As such, the high prevalence of multi-compartmental abscesses in our study underlines the significance of MRI as one of the primary imaging techniques sensitive to early inflammatory changes. MRI thus plays a very important role in identifying minor soft tissue abnormalities that are not usually picked up during a CT examination, especially in the early period of infection.¹²

On multivariate logistic regression analysis, age remained an independent predictor of vertebral body abscesses, with increased odds of forming an abscess for each additional year. The predictive value of age supports the hypothesis that advanced age contributes to the inflammatory and structural vulnerability of the spine. El-Sharkawi has also cited that elder patients with spondylodiscitis have a propensity for progressive complications due to impaired spinal vascularity and reduced healing potential.¹⁶

In resource-poor settings, timely diagnosis and management of spondylodiscitis pose considerable challenges. Advanced imaging is usually not available promptly in resource-

constrained settings. Therefore, diagnosing is delayed, with possible aggravation of the diseases. Balcescu et al, addressed resource constraints: "Regions with poor availability of MRI and other diagnostic modalities tend to have poorer outcomes in terms of spinal infection, higher complication rates, and chronic neurological deficits.¹⁷ As such, it agrees with our findings and points out the relevance of resource allocation in improving imaging capability, especially among high-risk demographics.

Our series also confirms that vertebral involvement and spinal cord compression are serious complications that bear immense importance in terms of patient outcome and the need for surgical intervention when conservative management may be insufficient. The indication for surgery is usually cord compression. The rate of cord compression in our series is high, estimated at approximately 36%, which is somewhat similar to that reported by Feun LG et al, in a series of patients with a spinal infection. This has pointed out the fact that patients with vertebral body involvement have to be followed up vigilantly given their increased risk of progression to cord compression, which may subsequently cause irreversible neurological deficits unless managed promptly.¹⁸

CONCLUSION

This review has underlined the fact that spondylodiscitis is a complex disease because of the complications with vertebral body involvement, formation of an abscess, and cord compression; therefore, the elderly are particularly affected by this disease. Age was a significant predictor of poor outcomes, which is important to recognize and thus suggests age-specific management. The most frequent levels of affection in the lumbar spine were L4-L5 and L5-S1, in line with previous studies that had established its susceptibility. Our findings emphasize MRI as the cornerstone for early diagnosis, especially in

resource-poor settings where delay in diagnosis often leads to poor outcome. Complication evolution identified, with the frequent combination of epidural and paravertebral abscesses, may allow for early intervention.

In essence, the study advocates for the strategy of greater imaging and an individualized approach to managing patient groups considered at higher risk, to minimize complications and optimally address spondylodiscitis, especially in resource-poor settings. Future studies should include multicenter, longitudinal data to provide a better understanding of the condition and its management in diverse settings.

LIMITATIONS

As a retrospective analysis, it relies on the accuracy and completeness of existing medical records, which may introduce biases and limit data consistency.

The study's single-center design restricts the generalizability of findings to broader populations.

The sample size, while adequate, may not capture all demographic and clinical variations.

Limited access to advanced imaging in resource-constrained environments may have led to underdiagnosed cases.

The absence of long-term follow-up restricts our understanding of the chronic progression and relapse risks.

REFERENCES

1. Landi A, Grasso G, Iaiani G, Gregori F, Mancarella C, Di Bartolomeo A, Domenicucci M, Delfini R. Spontaneous spinal discitis and spondylodiscitis: Clinicotherapeutic remarks. *Journal of neurosciences in rural practice*. 2017;642. Doi: 10.4103/jnrp.jnrp_265_17
2. Spennato P, Russo C, Cicala D, Colella G, Carannante N, Marini A, et al. *Spine Infection in Children. Pediatric Neurosurgery for Clinicians*: Springer; 2022. p. 747-69 Doi: 10.1007/978-3-030-80522-7_48

3. Zimmerli W. Osteomyelitis: classification. *Bone and Joint Infections: From Microbiology to Diagnostics and Treatment*. 2021:265-72.
4. Mancuso G, Midiri A, De Gaetano S, Ponzo E, Biondo C. Tackling drug-resistant tuberculosis: new challenges from the old pathogen *Mycobacterium tuberculosis*. *Microorganisms*. 2023:2277. Doi: 10.3390/microorganisms11092277
5. Mohme M, Stangenberg M, Mende KC. Impact of the localization on disease course and clinical management in spondylodiscitis. *Int J Infect Dis*. 2020. Doi: 10.1016/j.ijid.2020.07.028
6. Ibrahim A, Elshazly K. Management of spontaneous pyogenic spondylodiscitis: a descriptive cohort study. *Egypt J Neurosurg*. 2024. Doi: 10.1186/s41984-024-00299-0
7. Korwutthikulrangri E, Chaichompoo T. Radiographic evaluation of infective lumbar spondylodiscitis: A retrospective study. *J Orthop Sci*. 2023. Doi: 10.1016/j.jorep.2023.100161
8. El-Sharkawi MM, El-Sabrou M, Hassan MG. Spondylodiscitis: experience of surgical management of complicated cases. *Sicot J*. 2020. Doi: 10.1051/sicotj/2020002
9. Viezens L, Schaefer C, Helmers R. Spontaneous pyogenic spondylodiscitis in the thoracic or lumbar spine. *World Neurosurg*. 2017. Doi: 10.1016/j.wneu.2017.02.129
10. Govender S. Spinal infections. *The Journal of Bone & Joint Surgery British Volume*. 2005;87(11):1454-8. Doi: 10.1302/0301-620X.87B11.16294
11. Jain AK, Kumar J. Tuberculosis of spine: neurological deficit. *Eur Spine J*. 2019;28(9):2082-2091. Doi: 10.1007/s00586-019-06026-5
12. Lee HR, Cho JH, Lee D-H, Seok SY, Hwang CJ, Lee CS. Exploring the impact of mild-to-moderate foraminal stenosis at L5– S1 on clinical outcomes following L4– 5 posterior lumbar interbody fusion. *The Spine Journal*. 2024:820-30. Doi: 10.1016/j.spinee.2023.12.006
13. El-Sharkawi MM, Hassan OM, Ghoneim MM. Epidemiology of spondylodiscitis in low- and middle-income countries. *Infect Dis Clin North Am*. 2020;34(2):447-462. Doi: 10.1016/j.idc.2020.03.010
14. Li S, Du J, Huang Y, Gao S, Zhao Z, Chang Z, et al. From hyperglycemia to intervertebral disc damage: Exploring diabetic-induced disc degeneration. *Frontiers in immunology*. 2024;15:1355503. Doi: 10.3389/fimmu.2024.1355503
15. Son S, Lee SG, Kim WK, Ahn Y, Jung JM. Disc height discrepancy between supine and standing positions as a screening metric for discogenic back pain in patients with disc degeneration. *The Spine Journal*. 2021:71-9. Doi: 10.1016/j.spinee.2020.07.006
16. Kamal AM, El-Sharkawi MM, El-Sabrou M, Hassan MG. Spondylodiscitis: experience of surgical management of complicated cases after failed antibiotic treatment. *Sicot-J*. 2020. Doi: 10.1051/sicotj/2020002
17. Balcescu C, Odeh K, Rosinski A, Nudelman B, Schlauch A, Shah I, et al. Pyogenic spinal infections warrant a total spine MRI. *Journal of bone and joint infection*. 2023:1-9. Doi: 10.5194/jbji-8-1-2023.
18. Feun LG, Savaraj N, Bujnoski J, Nadeem S. Spinal cord compression produced by osteomyelitis mimicking spinal epidural metastasis. *American journal of clinical oncology*. 1992:174-9. Doi: 10.1097/00000421-199204000-00016.

Additional Information

Disclosures: Authors report no conflict of interest.

Ethical Review Board Approval: The study was conformed to the ethical review board requirements.

Human Subjects: Consent was obtained by all patients/participants in this study.

Conflicts of Interest:

In compliance with the ICMJE uniform disclosure form, all authors declare the following:

Financial Relationships: All authors have declared that they have no financial relationships at present or within the previous three years with any organizations that might have an interest in the submitted work.

Other Relationships: All authors have declared that there are no other relationships or activities that could appear to have influenced the submitted work.

AUTHORS CONTRIBUTIONS

| Serial Number | Author's Full Name | Intellectual Contribution to Paper in Terms of |
|---------------|---------------------|---|
| 1. | Mewat Shah | Study design and methodology. |
| 2. | Adnan Ahmad | Paper writing. |
| 3. | Muhammad Sajid | Data collection and calculations. |
| 4. | Abdur Raheem | Analysis of data and interpretation of results. |
| 5. | Muhammad Usman Khan | Literature review and referencing. |
| 6. | Nadeem Ullah | Editing and quality insurer. |