

# Surgical Outcome of Chiari Malformation Type One in Adults

IHSANULLAH, KHALID KHANZADA, MUSAFIRA ALAM, HAMEEDULLAH

Department of Neurosurgery, Medical Teaching Institution, Govt. Lady Reading Hospital, Peshawar

## ABSTRACT

**Objective:** To assess the post-operative outcome after Posterior Fossa Decompression (PFD) with duraplasty in Chiari-I malformations.

**Study Design:** Case series.

**Place and Duration of Study:** Department of Neurosurgery, Medical Teaching Institution Lady Reading Hospital Peshawar, from January 2013 to June 2018.

**Materials and Methods:** This study included 28 patients of Chiari 1 malformations admitted through OPD with the presentation of suboccipital headache, neck pain, dizziness/fatigue, numbness and paresthesias in upper limbs, gait problem, cerebellar dysfunction and or with syringomyelic syndrome. MRI whole spine and CT scan brain was done in all cases to confirm diagnosis and rule out other pathologies. Suboccipital craniectomy with C1 laminectomy and expansile duraplasty was performed in all cases and clinical outcome was assessed in follow-up clinic.

**Results:** Among 28 patients, 16 were females and 12 males. Age ranged from 16 to 48 years with a mean of 26 years. Headache were present in 22, neck pain in 17, fatigue and dizziness in 14, numbness and paresthesia of upper limbs in 12, loss of fine motor skills in 8, cerebellar dysfunction in 5 and sphincter loss in 4 patients. Mean time to diagnosis was 14 months. Syrinx was present in all patients. Posterior fossa decompression with duraplasty with an additional C1 laminectomy was performed in all cases. Syringo-subarachnoid shunt was placed in one patient. Pain was relieved in 78.5% of cases. Postoperative outcome was assessed as good, fair and poor based on pre and post-operative clinical and radiological parameters. Good outcome was noted in 22 patients and fair in 6 cases in this series. No patient suffered a in our series. Syringomyelia was improved in all except one case in which it improved after syringo subarachnoid shunt. Postoperative morbidity included CSF leak in 2 patients, superficial wound infection in 2 patients.

**Conclusion:** Posterior fossa decompression with C1 laminectomy followed by expansile duraplasty is the main surgical modality of treatment for Chiari-I malformation. Better post-operative outcome is achieved with PFD in terms of symptoms, reduction in syrinx size, with minimum surgical morbidity and mortality.

**Abbreviations:** CM-I: Chiari Malformation Type I. CSF: Cerebrospinal Fluid. C1: C1 Laminectomy. FPD: Posterior Fossa Decompression.

**Key Words:** Chiari-I malformation, Syringomyelia, Posterior fossa decompression, Duraplasty.

## INTRODUCTION

Chiari malformation was first described by the pathologist Hans Chiari in 1891. His observation was based on 40 autopsies; He recognized four types (Type I-IV) based on the amount of structural herniation from posterior fossa to spinal cord.<sup>1,2</sup> Chiari malformation type I (CM-I) is characterized by

cerebellar tonsil herniation to the spinal canal at least 5 mm below through the foramen magnum without involving the brainstem. Syringomyelia (cystic cavitation of the spinal cord) is also present in about 32-73% of cases with CM-I.<sup>2-4</sup> Obstruction in cerebrospinal fluid (CSF) pathways is the cause of all these anatomical changes. Hydrocephalus is also

present in about 10% of cases.<sup>2,4,6</sup> The cerebrospinal fluid outflow is due to phase difference in the outflow and influx of blood to the brain. Chiari 1.5 malformation has been described recently and differs slightly from CM-1 in downward herniation of the brain stem but both share the same management. The four known varieties of Chiari malformations have different degrees of rhombencephalic structures involvement.<sup>3,4,7,8</sup> Three of these malformations (type I to III) have progressively more severe herniation of the posterior fossa contents and have loss of free movement of cerebral spinal fluid (CSF) out the fourth ventricle to the spinal subarachnoid space and then back to cortical subarachnoid space. Differences between development of type I and type II can be explained best due to a difference in the timing of the embryologic development of the posterior fossa structures. Congenital variety is most common, but acquired CMs also occur and are not rare. Supratentorial mass lesion can also cause herniation of posterior fossa contents.<sup>5,6</sup> CM-I commonly present with headaches, myelopathy, fatigue, dizziness, nausea, swallowing problem, impaired coordination, and, in severe cases, paralysis. Controversy exists regarding surgical treatment of CM1.<sup>3,7,9,10</sup>

The objective of this study was to determine the symptomatic outcome and complications after posterior fossa decompression (PFD) with an additional C1 Laminectomy (CL) followed by duraplasty in CM-1. Suboccipital craniectomy is a main surgical modality for treatment with some modifications like C1 laminectomy, dural opening with duraplasty, arachnoid opening (lysis of adhesion), subpial resection and coagulation of tonsils.

## MATERIALS AND METHODS

This is a prospective study of 28 patients diagnosed as Chiari malformation type I (CM-1) at the Department of Neurosurgery, Medical Teaching Institution Lady Reading Hospital Peshawar from Jan 2013 to June 2018. All Patients were admitted through outpatient department, age ranged between 16-55 years and with progressive symptom without high medical risk. We excluded patients out of the age range, asymptomatic patients, symptomatic patients with static course, patients with severe medical condition excluding anesthesia or those previously operated. All data were collected preoperatively on a Proforma regarding age, sex, medical history, present history, general examination, ophthalmologic assessment and full

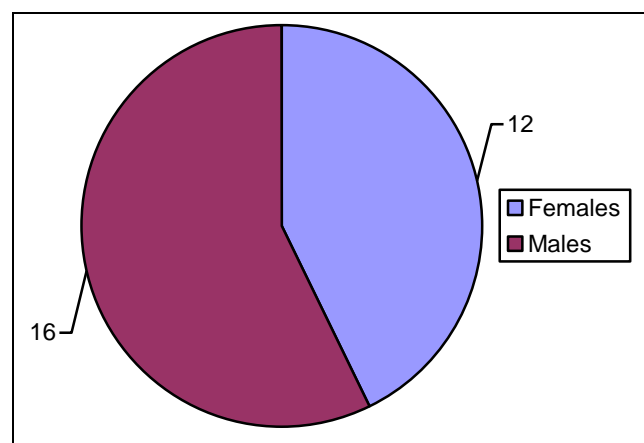
neurological examination. All patients were investigated by CT brain, MRI spine plus craniocervical junction and follow up post-operative MRI 6 months later. Informed consent was taken from all patients. A standard midline incision was given in all cases starting frominion to C2 spinous process, posterior fossa craniectomy with opening of the foramen magnum (3x3cm) were performed in all cases, after dural opening expansile duraplasty was done using pericranial graft, obtained through the same incision.

Postoperative neurological status was assessed on post-operative day one. The data was again collected on a Proforma. After discharge from hospital patient was followed-up subsequently in OPD after 2 weeks, then 3 and 6 months later. The evaluation was done both clinically regarding any improvement or deterioration in the symptomatology and radiologically (MRI & CT scan) to detect hydrocephalus or enlargement of syrinx.

## RESULTS

### Age and Sex Distribution

Out of the total 28 cases 16 were females and males 12 with a ratio of 1.33/1. The mean age at the time of surgery for the studied group was 26 years ranging from 16 to 55 years.



**Fig. 1:** Gender Distribution.

Duration of symptoms ranged from 2 months to 6 years. Average time to diagnosis was 14 months. The most common clinical findings presented at diagnosis were headache in 22 patients, neck pain in 17 patients, dizziness and fatigue in 14, numbness and paraesthesia

in upper limbs in 12 patients, weakness of fine movements of hands in 8 patients, spasticity in the lower limbs in 5 patients, sphincter dysfunction in 4 patients, cerebellar signs in 5 patients. Classic finding of downbeat nystagmus described in literature were observed only in 2 patients (Table 1).

**Table 1.**

Presentation	Number	Percentage
Headache (suboccipital)	22	78.5
Neck pain	17	60
Dizziness and Fatigue	14	50
Numbness/paresthesias in upper limbs	12	42.8
Loss of fine motor movement	8	28.5
Gait problem(spasticity in lower limbs)	5	17.8
Sphincter dysfunction	4	14.28
Cerebellar signs	5	17.85

### Clinical Outcome

It was assessed as:

- a) Good:** patients having marked improvement with no residual symptoms causing any sort of disability.
- b) Fair:** patients having residual symptoms causing mild disability in performing their usual daily activities.
- c) Poor:** patients having no improvement at all.

Good clinical outcome was noted in 22 patients, fair in 6 patients. Poor outcome was not noted in the whole series (Table 2).

**Table 2:**

Postoperative Outcome	Number of Patients	Percentage
Good	22	78.5
Fair	6	21.5
Poor	0	0

### DISCUSSION

CM1 is described as the cerebellar tonsils herniation

out of its normal confines in posterior fossa to the cervical spinal canal, 5mm below the foramen magnum. It is associated with syrinx in 45 - 74% of the cases<sup>1,2,5,7,12</sup> Hydrocephalus is also present in about 1 - 10%. Associated abnormalities like basilar invagination, Klippel-Feil syndrome, platybasia, scoliosis, short neck are also seen along with these malformations. Pathogenesis is still poorly understood despite advances in medical sciences.<sup>4,9,10,13</sup> Theories have been proposed regarding its pathogenesis, but none is universally accepted. The most popular theories include **Gardner's hydrodynamic** theory, Williams's theory of craniospinal dissociation, Aboulker theory, Greitz theory and Oldfield theory.<sup>11,14,15</sup>

Common modes of presentation are suboccipital headache, neck pain, numbness and weakness of the hands, spasticity of the lower limbs and sphincteric dysfunction. Same results were reflected by Wilkinson et al.<sup>11</sup> and Deng X et al.<sup>15</sup>

Where syringomyelia exists as in 45 - 74% of cases, treatment is required. PFD is a main surgical procedure to treat CM-1. After surgery syrinx size significantly reduced in first 6 months. Craniocervical decompression (3x3cm craniectomy plus C1 laminectomy) with expansile duraplasty using pericranial graft, far lateral foramen magnum decompression, Subpial resection of tonsils and syngo-subarachnoid shunt have been used in various circumstances as a surgical treatment options. Syngo-subarachnoid shunt has been advocated for cases where there is persistent syrinx after PFD. Ventriculo-subarachnoid shunt and syngo-peritoneal shunt are other options in such recalcitrant cases. Another study showed that PFD, C1 laminectomy and duraplasty for the treatment of CM-1 may lead to a more reliable reduction in the volume of syrinx, compared with PFD and C1 laminectomy alone. In our as almost all cases improved with the disappearance of syrinx formation after this approach which is comparable to those of Alden et al.<sup>5</sup> Although PFD remains the first line treatment in patients with Chiari-1 malformations complicated by syringomyelia in many cases. Rehman et al proposed that clinical symptoms and radiological findings improved much more quickly in the patients in whom syngo-subarachnoid shunting was done.<sup>1,16</sup> A large syrinx failed to regress in size after PFD in one patient with persistence of symptoms. So syngo-subarachnoid shunting was done after 2 years, which resulted in the collapse of syrinx along with improvement in

symptoms in this patient. Syringo-subarachnoid shunt can be used in resistant cases in which the syrinx size remains the same after PFD and with the persistence of symptom. Regression of symptoms and clinical improvement was seen in most of the patients after surgery. In a few patients, no improvement was noted in fine motor skills and sensory symptom also persisted after PFD. As late presentation was noted in all these cases and is probably the reason for no improvement after surgery. However, the most likely PFD will halt the progression in these patients. It has been observed, in patients with Chiari associated syringomyelia, that motor symptoms are more likely to improve with hindbrain decompression than sensory symptoms.<sup>1</sup> However, Kennedy et al. concluded from a series of 156 patients that pain was most likely to resolve than sensory and motor deficit after decompressive surgery in such patients<sup>9</sup>. Surgical intervention in such malformations has been associated with a wide spectrum of intraoperative and postoperative complications. The complication rate in this series was 14.2%. Knowledge of all possible complications is important for their complete prevention and to take specific precautions to minimize its occurrence and also for the management when they do occur. Understanding of posterior fossa microsurgical anatomy is mandatory to avoid any neurological or vascular injuries.<sup>14,15</sup> Altered posterior fossa anatomy due to hind brain herniation makes these patients susceptible to vascular and neural injuries. Vertebral artery injury occurred in one of the patients in our study, but was managed with coagulation of the vessel and no post op deficit was observed. Cerebrospinal fluid leak is well recognized postoperative common complication after PFD with duraplasty. Thus water-tight dural closure is important for avoiding any postoperative leaks. Best suture material for dural closure is 4-0 silk suture and using interrupted stitches, as running stitches may loosen or pull out. Cerebrospinal fluid leak should also be confirmed by Valsalva maneuver before closure of the wound. Post op CSF leak can present as a leak from incision, bacterial or aseptic meningitis, hydrocephalus, pseudomeningocele or wound dehiscence.<sup>17</sup> Despite taking all the precautions during closure of the dura and, thereafter, checking for leak by Valsalva maneuver, CSF leak was observed in two patients. Both these patients were managed, non-operatively. The leak stopped after a few days in one patient with reinforcement stitches and the rest. However, it was managed by placing a lumbar drain as

the leak was not responding to other conservative measures. Leakage of CSF stopped at 10 days and the patient discharged with no further complication.<sup>18</sup>

Deaths have been reported in literature after PFD for Chiari malformations, with a reported mortality rate of 1-3%. In our study there was no mortality.

## CONCLUSION

Clinical improvement was noted in all patients after PFD with duraplasty and therefore it is a safe and effective technique in terms of improvement of symptoms, complications and to halt the progression of disease.

*Address for Correspondence*

*Dr. Khalid Khanzada*

*Assistant Professor*

*Dept. of neurosurgery MTI, LRH, Peshawar*

*Email: drihsan.ns@gmail.com*

*musafir48@hotmail.com*

## ROLE OF AUTHORS

Dr. Ihsanullah. Paper Writing.

Dr. Khalid Khanzada. Literature Search.

Dr. Musafira Alam. Tables and Graphs.

Dr. Hameedullah. Proof Reading.

## REFERENCES

1. Rehman L, Akbar H, Bokhari I, Babar AK, A. Hashim SM, Arain SH, "Posterior Fossa Decompression with Duraplasty in Chiari-1 Malformations". JCPs. 2015; 25 (4): 254-258.
2. Kalemci O, Yilmaz M, Ur K, Arda MN. Decompression of the foramen magnum without burr hole for treatment of Chiari malformation type-1: report of 25 cases. JNS (Turkish), 2014; 31: 744-51.
3. Abila AA, Link T, Fusco D, Wilson DA, Sonntag V. Comparison of dural grafts in Chiari decompression surgery: review of the literature. J Craniovert Jun Spine, 2010; 1: 29-37.
4. Khan AA, Bhatti SZ, Khan G, Ahmed E, Aurangzeb A, Ali A, et al. Clinical and radiological findings in Arnold Chiari malformation. J Ayub Med Coll Abbottabad 2010; 22: 76.
5. Alden TD, Ojemann JG, Park TS. Surgical treatment of Chiari-1 malformation: indications and approaches. Neurosurg Focus, 2001; 11.
6. Mottolese C, Szathmari A, Simon E, Rousselle C, Ricci- Franchi AC, Hermier M. Treatment of Chiari

- type-1 malformation in children: the experience of Lyon. *Neurologic Sci* 2011; 32: S325-30.
7. Battal B, Kocaoglu M, Bulakbasi N, Husmen G, Tuba Sanal H, Tayfun C. Cerebrospinal fluid flow imaging by using phasecontrast MR technique. *Br J Radiol*. 2011; 84: 758-65.
  8. Siasios J, Kapsalaki EZ, Fountas KN. Surgical management of patients with chiari-I malformation. *Int J Pediatr*. 2012; 1: 10.
  9. Kennedy et al. "Outcomes after suboccipital decompression without dural opening in children with Chiari malformation Type I." *J Neurosurg Pediatr*. 2015 August; 16 (2): 150–158.
  10. McVige JW, Leonardo J. Neuroimaging and the clinical manifestations of Chiari malformation type I (CMI). *Curr Pain Headache Rep*. 2015; 19: 18.
  11. Wilkinson et al "Trends in surgical treatment of Chiari malformation Type I in the United States". *J Neurosurg Pediatr*. 2017; 19: 208–216.
  12. Chen et al. Comparison of posterior fossa decompression with and without duraplasty for the surgical treatment of Chiari malformation type I in adult patients. A retrospective analysis of 103 patients *Medicine*, 2017; 96: 4.
  13. Ma J, You C, Chen H, et al. Cerebellar tonsillectomy with suboccipital decompression and duraplasty by small incision for Chiari I malformation (with syringomyelia): long term follow-up of 76 surgically treated cases. *Turk Neurosurg*. 2012; 22: 274–9.
  14. Chotai S, Medhkour A. Surgical outcomes after posterior fossa decompression with and without duraplasty in Chiari malformation-I. *Clin Neurol Neurosurg*. 2014; 125: 182–8.
  15. Deng X, Yang C, Gan J, et al. Long-term outcomes after small-bone window posterior fossa decompression and duraplasty in adults with Chiari malformation type I. *World Neurosurg*. 2015; 84: 998–1004.
  16. Bowers CA, Brimley C, Cole C, et al. Allo Derm for duraplasty in Chiari malformation: superior outcomes. *Acta Neurochir (Wien)*, 2015; 157: 507–11.
  17. Siasios J, Kapsalaki EZ, Fountas KN. Surgical management of patients with Chiari I malformation. *Int J Pediatr*. 2012: 640127.
  18. Ahmed M K, Ehab A A, Hanan H. Surgical Management of Chiari Malformation Type One in Adults. *Tech Neurosurg Neurol*. 1 (3).

Date of Submission: 25-1-2019

Date of Printing: 15-3-2019