

Case Report

Experience with Ventriculoatrial Shunt: A Valid Option

Muna Saleh Alnamlah¹, Muhammad Sohail Umerani², Amjad Abdel Qader Darwish²

Muhammad Shamoon Umerani³, Asad Abbas⁴

Department of Neurosurgery, ¹King Fahd University, ²King Fahd Military Medical Complex, Dhahran, KSA. ³Al-Hussan International Schools, Jubail, KSA. ⁴Nottingham University Hospital, Nottingham, UK

ABSTRACT

Cerebrospinal fluid (CSF) diversion either internal or external, is the standard of care for hydrocephalus. Although Ventriculoperitoneal (VP) shunt is usually the first choice for internal CSF diversion, right atrium for Ventriculoatrial (VA) shunt can be considered a suitable and convenient option for drainage of CSF in patients with a history of abdominal surgery, peritoneal infection or shunt obstruction.¹ We report our experience with a patient who underwent VA shunt insertion because of a previous malfunctioning VP shunt. A thorough review of the literature revealed that, although reported worldwide, there is an apparent deficiency of similar reports from the Arabian Gulf region. Through this case report, we aim to highlight this CSF diversion procedure, which can be considered in centers lacking advanced care facilities for procedures like Endoscopic 3rd Ventriculostomy (ETV).

Keywords: Ventriculoatrial (VA) shunt, Ventriculoperitoneal (VP) shunt, shunt obstruction, CSF diversion, Surgical options

Corresponding Author: Asad Abbas

Department of Neurosurgery,
Nottingham University Hospital, Queens Medical Center
Nottingham, UK
Email: asad.abbas@live.com

Date of Submission: 17-11-2020

Date of Revision: 05-12-2020

Date of Online Publishing: 25-12-2020

Date of Print: 30-12-2020

DOI: 10.36552/pjns.v24i4.437

INTRODUCTION

Prior to the introduction of the current advance CSF diversion procedures, hydrocephalus was

managed by various techniques, e.g. head wrapping however, it was not therapeutic. Percutaneous drainage was also practiced for centuries, with evidence going back as early as 1465. However, those attempts were mostly futile due to high mortality attributed to infections. After the introduction of anesthesia and aseptic techniques in the late 1800s, surgical drainage proved to be a rather successful procedure in its management. Neurosurgeons continued to improve on existing methods, resulting in the introduction of what is considered to be the most effective procedure to date in the treatment of hydrocephalus; ventricular shunts. Since then, not only the shunts have undergone continuous

modifications, the procedure for the distal end have evolved to meet the challenges of the modern era.²

CASE REPORT

A 27 year old female who had undergone VP shunt insertion at the age of 8 months of post-traumatic hydrocephalus. She had been bed bound ever since. The VP shunt was revised 2 to 3 times in the last 10 years. She presented to the Emergency Department (ED) with complaints of abdominal distention, decreased oral intake and increased lethargy for 3 weeks. On examination the patient had decreased level of consciousness. Although vitally stable and afebrile, clinical examination revealed abdominal distension with mild to moderate tenderness at the left iliac fossa. The shunt reservoir was also difficult to compress. Her initial laboratory investigations were unremarkable for any systemic infection or metabolic derangement. Computed Tomography (CT) scan of the abdomen with contrast, showed large cystic, intra-peritoneal, non-contrast enhancing collection around the distal end of the shunt (Fig. 1&2).

The mass with dimensions of 22 cm craniocaudally, 15 cm anteroposterior and 16 cm in width, was displacing the small bowel and transverse colon. The distal end of the tube could be seen within the cyst and there was no kinking. CT brain revealed ventriculomegaly without acute hydrocephalus. The family was counseled regarding the diagnosis of distal shunt obstruction. She underwent shunt exteriorization and open drainage of peritoneal collection, with the help of the General Surgery team.

After the initial procedure her neurological condition improved and she started obeying commands with normal oral intake. Blood and CSF cultures were unremarkable. In view of her presenting abdominal condition, the family was consented for placement of a VA shunt in the right atrium. Per operative, the left internal

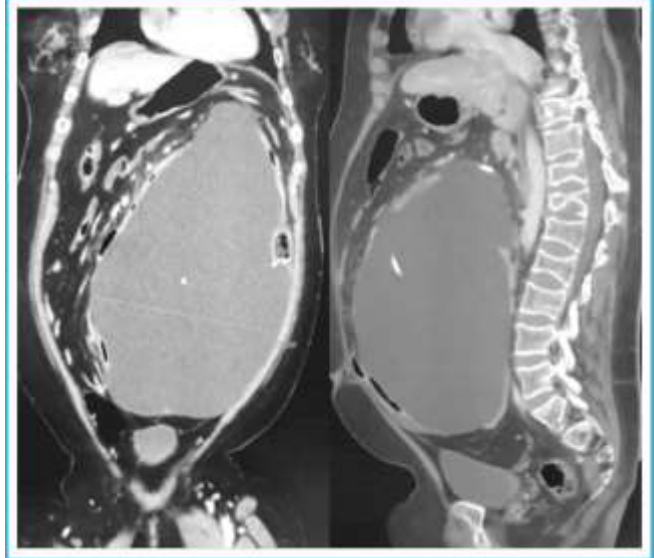


Figure 1: CT scan of the abdomen with contrast, coronal or sagittal views, showing large cystic, intra peritoneal, non-contrast enhancing collection around the distal end of the shunt.

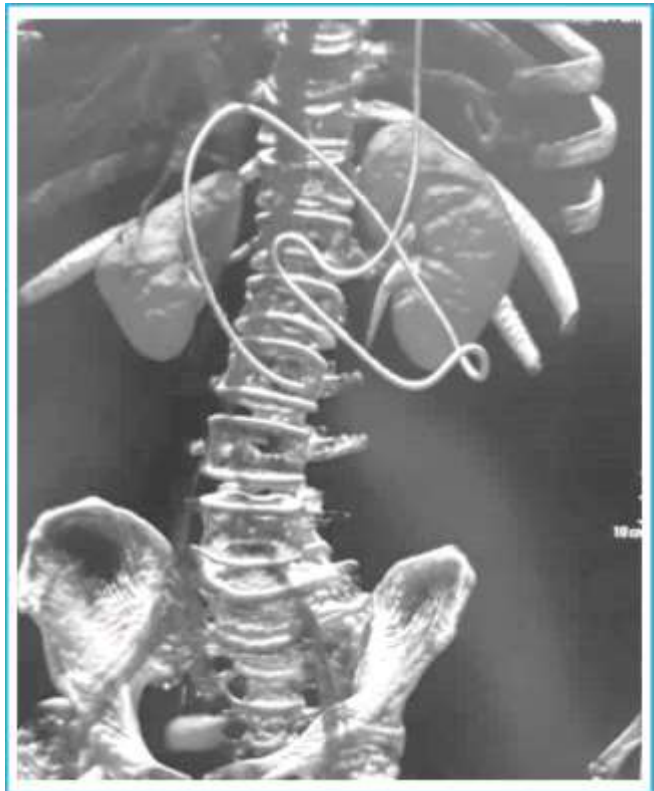

Figure 2: CT scan 3-D reconstruction of the abdomen showing the peritoneal tube of the VP Shunt with no evidence of kinking.

jugular vein was dissected out and the catheter was passed through it under fluoroscopic guidance and Echocardiography (ECG). The distal tip was advanced up to 4th thoracic vertebra. Postoperatively the patient had an unremarkable recovery. Follow up ultrasound abdomen was negative for any residual collection and chest X-ray showed satisfactory position of the distal tip of the VA shunt.

DISCUSSION

CSF can either be diverted internally, through shunts, or externally, using External Ventricular Drain (EVD). Comparisons have been drawn in the literature between the two methods, and most agreed that EVD, while effective for only short periods, carries higher risk of complications, such as hemorrhage and infection.^{3,4} The continuously evolving shunt system is generally comprised of a proximal ventricular catheter, a one-way valve system and a distal catheter.⁵

The most important decision to make when opting for a shunt is the site of distal catheter. Over the years, various sites in the body were employed for the purpose of draining CSF, the most common and successful one the peritoneum followed by right atrium and pleura.^{5,6} VP shunts are considered the standard of care for hydrocephalus, due to their success rate and safety compared to ventriculoatrial (VA) and ventriculopleural (VPL) shunts; which are less likely to cause over-drainage.^{4,6} But in the event of multiple abdominal surgeries, peritoneal adhesions, infection or ascites, VP shunt is considered a contraindication, leaving VA or VPL shunts a valid option, depending on the patient's condition.⁷

Neurosurgeons experimented with shunt as a management of hydrocephalus throughout the first half of the 20th century; in 1951 the successful treatment hydrocephalus was reported by Nulsen & Spitz. Four years later in 1955, Pudenz introduced the VA shunt which he used it in the

treatment of a 3 months old child. Pudenz's shunt system comprised of 3 parts: a ventricular tube with perforations by the sides of the tip that contained tantalum powder for X-ray contrast, a flushing device with a valve allowing unidirectional flow, and a cardiac tube with 4 slit valves near its tip.⁸ They are considered inferior to VP shunts due to higher reported complications including mechanical failure, pulmonary hypertension, glomerulonephritis, septicemia, and thrombosis leading to pulmonary embolism. Therefore it is prudent to take certain precautions, including proper placement of the cardiac tube's tip at the dorsal vertebra 5 to 6 level.⁸

Murakami M, et al. reported a case of pregnant patient with a malfunctioning VP shunt due to the physiological increase in intra-abdominal pressure. Hence a shift to VA shunt was essential for the safety of both mother and fetus.⁹ A similar case reported the details of conversion from VP to VA shunt in a 3 month old girl, who had myelomeningocele with Chiari II malformation. She presented with small bowel ischemia and necrosis due to coiling of the peritoneal catheter. Her symptoms resolved after successful resection of necrotic bowel and insertion of VA shunt.¹⁰ Literature has shown reports of VPL shunt being associated with pleural effusion, fibrothorax, empyema, and occasionally, galactorrhea. Since this method is also commonly supplemented with frequent thoracentesis to avoid the development of severe pleural effusion, its success has fallen into disrepute.^{11,12} Zhang J, et al, reviewed his 6 cases of hydrocephalus with multiple previous VP shunt failures. These were successfully converted to VA shunts, following a percutaneous rather than an open surgical approach. None of the patients experienced any adverse events, and all improved clinically.⁷

Our patient had VP shunt revisions earlier for various reasons and at presentation had a large localized pseudo-cyst, leaving VA shunt an option to avoid the recurrence of shunt externalization and ascites. Even supported by literature, VA

shunt was favored over VPL shunt since our patient was bedridden and was at risk of developing pleural effusion if the latter was opted.

CONCLUSION

Hostile peritoneum can cause distal catheter obstruction of VP shunt. Before embarking on to the decision of revision from VP to a VA shunt, prompt identification of the site and cause of distal obstruction is to be taken in to account. This is confirmed by detailed history and examination with appropriate radiological investigations. Once a functioning VA shunt is placed, close follow up is obligatory for early signs for potential life threatening complications.

REFERENCES

1. Karahan O, Yavuz C, Demirtas S, Caliskan A, Kamasak K, Guclu O et al. Reasons, procedures, and outcomes in ventriculoatrial shunts: A single-center experience. *Surgical Neurology International*, 2013; 4 (1): 10.
2. Rachel R. Surgical Treatment of Hydrocephalus: A Historical Perspective. *Pediatric Neurosurgery*, 1999; 30 (6): 296-304.
3. Nee L, Harun R, Sellamuthu P, Idris Z. Comparison between ventriculosubgaleal shunt and extraventricular drainage to treat acute hydrocephalus in adults. *Asian Journal of Neurosurgery*, 2017; 12 (4): 659.
4. Ko J, Cha S, Choi B, Lee J, Yun E, Choi C. Hemorrhage Rates Associated with Two Methods of Ventriculostomy: External Ventricular Drainage vs. Ventriculoperitoneal Shunt Procedure. *Neurologia medico-chirurgica*. 2014; 54 (7): 545-51.
5. Pople I. Hydrocephalus and shunts: what the neurologist should know. *Journal of Neurology, Neurosurgery, Psychiatry*, 2002; 73: 17-22.
6. Garton H. Cerebrospinal Fluid Diversion Procedures. *Journal of Neuro-Ophthalmology*, 2004; 24 (2): 146-155.
7. Zhang J, Qu C, Wang Z, Wang C, Ding X, Pan S et al. Improved ventriculoatrial shunt for cerebrospinal fluid diversion after multiple ventriculoperitoneal shunt failures. *Surgical Neurology*, 2009; 72: S29-S33.
8. Konar S, Maiti T, Bir S, Kalakoti P, Nanda A, Robert H. Pudenz (1911–1998) and Ventriculoatrial Shunt: Historical Perspective. *World Neurosurgery*, 2015; 84 (5): 1437-40.
9. Murakami M, Morine M, Iwasa T, Takahashi Y, Miyamoto T, Hon PK, Nakagawa Y. Management of maternal hydrocephalus requires replacement of ventriculoperitoneal shunt with ventriculoatrial shunt: a case report. *Arch Gynecol Obstet*. 2010; 282: 339–42.
10. Tan LA, Kasliwal MK, Moftakhar R, Munoz LF. Ventriculoperitoneal shunt with a rare twist: small-bowel ischemia and necrosis secondary to knotting of peritoneal catheter. *J Neurosurg Pediatrics*, 2014; 14: 234–37.
11. Morón M, Barrow D. Cerebrospinal fluid galactorrhea after ventriculopleural shunting: Case report. *Surgical Neurology*, 1994; 42 (3): 227-30.
12. Willison C, Kopitnik T, Gustafson R, Kaufman H. Ventriculopleural shunting used as a temporary diversion. *Acta Neurochirurgica*. 1992; 115 (1-2): 67-8.

Additional Information

Disclosures: Authors report no conflict of interest.

Human Subjects: Consent was obtained by all patient(s)/participant(s) in this study.

Conflicts of Interest:

In compliance with the ICMJE uniform disclosure form, all authors declare the following:

Financial Relationships: All authors have declared that they have no financial relationships at present or within the previous three years with any organizations that might have an interest in the submitted work.

Other Relationships: All authors have declared that there are no other relationships or activities that could appear to have influenced the submitted work.

AUTHORS CONTRIBUTIONS

Sr.#	Author's Full Name	Intellectual Contribution to Paper in Terms of:
1.	Muna Saleh Alnamlah	1. Study design and methodology.
2.	Muhammad Sohail Umerani	2. Paper writing, referencing, and data calculations
3.	Amjad Abdel Qader Darwish	3. Data collection and calculations.
4.	Muhammad Shamoon Umerani	4. Analysis of data and interpretation of results.
5.	Asad Abbas	5. Literature review and manuscript writing.