

Original Article

Outcome Comparison of Endoscopic (Endonasal Trans-Sphenoidal) Repairs of CSS Leak vs. Transcranial Approach

Ishfaque Ahmed Simair¹, Jawad Ali¹, Abid Khattak¹, Amjad Qureshi², Tarique Salah-ud-Din¹

¹AMC/Post Graduate Medical Institute (PGMI), Punjab Institute of Neurological Sciences (PINS), Department of Neurosurgery, Lahore General Hospital (LGH), Lahore, Pakistan

²Department of Neurosurgery, Agha Khan University Hospital, Karachi, Pakistan

ABSTRACT

Background & Objective: Cerebrospinal fluid (CSF) leak and its management became controversial since decades. Either managed conservatively or repair surgically through open trans-cranial approach or endoscopic through trans-nasal approach. The study was aimed to compare the effectiveness of Endoscopic (Endonasal transsphenoidal) repair of CSF leak with transcranial approach in terms of post-operative complications like infection, recurrence and hospital stay.

Material and Methods: The comparative experimental randomized study was conducted in the Department of Neurosurgery Unit I, PGMI, Lahore General Hospital, Lahore. After approval from ethical committee this study was carried out in our unit. 40 subjects with the history of CSF leak were randomly divided into two groups; one was treated with endonasal trans-sphenoidal repair and another was treated with trans-cranial approach, the subjects were followed up for 1 year. Detailed history, neurological examination, preoperative CT and MRI scans were performed in all patients.

Results: The mean age of patients with CSF leak was 25.58 ± 14.38 years. Among the patients, 17 were females and 23 were male. The mean age of the female was 31.70 ± 14.29 years. The mean age of the male was 21.04 ± 12.95 . The recurrence was observed in 2 (10%) of the patients treated with endoscopic technique and 1 (5%) of the patients treated with trans-cranial approach. Those patients were successfully repaired in a second operation. Overall success rate was 92.5%. One patient (2.50%) among the trans-cranial approach develops infection which was treated successfully.

Conclusion: The endoscopic repair of CSF leak is both safe and effective and should be considered as the standard procedure of choice in most of the cases.

Keywords: Cerebrospinal Fluid Leak (CSF Leak), Rhinorrhea, Tran-sphenoidal, Endo nasal repair, Trans-cranial approach.

Corresponding Author: Ishfaque Ahmed Simair
Department of Neurosurgery, Lahore General Hospital (LGH),
Lahore, Pakistan. Email: ishfaquesimair@gmail.com

Date of Submission: 28-11-2020
Date of Revision: 12-01-2021
Date of Online Publishing: 31-03-2021
Date of Print: 31-03-2021

Doi: 10.36552/pjns.v25i1.527

INTRODUCTION

Brain and spinal cord are surrounded by a membrane which is called dura matter, any tear in this membrane leads to egress of fluid from the brain and spinal cord through this membrane. This liquid is known as cerebrospinal fluid (CSF) which leads to decrease in pressure around the brain and spinal cord if leakage of CSF occurs through any tear. Most of the patients present with colorless and clear, watery discharge usually from one nostril or ear may be present from both (Rhinorrhea). This leak may become more profound, visible and even continuous when patient bend forward or he/she has straining either because of constipation or coughing. Patient may present with deterioration of vision, headache and hearing loss. CSF leaks have two major types: Spontaneous leaks develop without any reason and traumatic leaks developed when patients underwent any surgery, trauma or tumors.¹

The management of CSF leak (CSF Fistula) depends on the cause, first we have to confirm that watery discharge is CSF leak. There are many clinical tests like Halo sign and Reservoir sign, but β -2 transferrin is specifically for cerebrospinal fluid. The β 2-transferrin levels have been commonly used for the diagnosis of extra-cranial CSF fistula, with a reported sensitivity and specificity of up to 99% and 97%, respectively.² Traumatic CSF leak is usually managed conservatively by putting a lumbar drain in order to give a diversion for healing of a small tear. Around 90% of CSF leaks heal spontaneously and do not require any surgical procedure. While CSF leaks at the base of skull during surgery usually requires surgical repair.¹

When localizing the site of CSF fistula we use: 1) CT scan: to detect pneumocephalus, fractures, skull base defects, hydrocephalus and obstructive neoplasms. Including thin coronal cuts or reconstruction through anterior fossa all the way back to the sella turcica. (A) Plain CT scan: to

demonstrate bony anatomy and (B) CT scan with IV contrast: leak site is usually associated with abnormal enhancement of adjacent brain parenchyma (possibly from inflammation), 2) Water soluble contrast CT Cisternography (Investigation of Choice) and 3) MRI: may provide additional information for localization and rule out posterior fossa mass, tumor and empty sella better than CT. Both CT and MRI can rule out hydrocephalus. T2WI (T2 weighted images) have been used to visualize CSF flow.

Water soluble contrast CT Cisternography is indicated and if we are unable to locate the CSF leak on plain CT scan or when the patient is leaking clinically and lastly, where several bony defects are found, deciding which location is actively leaking is utmost important. Last but not the least, if a bony defect seen on plain CT scan does not associated changes of abnormal enhancement of adjacent brain parenchyma.

There are two treatment options: medical or surgical. Conservative treatment is usually reserved for CSF leaks in head injury patients and spontaneous leaks. Conservative management starts from bed rest for 1-2 weeks, avoidance of increase intra-abdominal pressure like coughing, sneezing and weight lifting which can ultimately culminate in recurrence of CSF leak. A few patients may need Lumbar drain as a diversion procedure.

Indications for surgical intervention are: traumatic CSF leak that persists > 2 weeks in spite of non-surgical measures, spontaneous leaks and those of delayed onset following trauma or surgery: usually require surgery because of high incidence of occurrence and leaks complicated by recurrent meningitis.³

When conservative treatment is fails, we have different surgical options for CSF leaks: transcranial and endoscopic. In both the procedures the defect is usually repaired primarily or graft is applied for reinforcement. The graft can be taken from fascia lata or abdomen (like fat). Fibrin Glue is also used as a sealant. We used

Fibrin glue in almost all cases except two of transcranial approach.

The frontal craniotomy and the subfrontal approach are the most common transcranial approaches that are used. If the frontal sinuses have been exposed after surgery, they must be stripped of mucosa and packed (exsanguination), and supported by layer of pericranial, muscle patch or fascia lata followed by Fibrin glue which work as adhesive agent. Bone flap is replaced back and re-sutured.⁴

Trans-cranial approach has a higher rate of complications than the trans-sphenoidal approach like hematoma formation and infection. Trans-cranial approach carries 3-4% risks of seizures because of brain retraction. These patients are advised to avoid driving for about 1 year. This complication is not associated with transsphenoidal approach. In some literature, the failure rate of trans-cranial approach is quoted as high as 25%.⁵

Trans-sphenoidal repair of CSF leak requires endoscope through the nasal cavity which gives direct, clear and magnified visualization. Surgeon can use Fluorescein dye if CSF leak is not identified pre-operatively, which give green yellow color.⁶ If the defect is small, one layer is sufficient and if it is large, multi-layered graft is applied. (On lay and inlay graft). Fibrin glue is applied as a sealant to anchor the graft at one place. Few surgeons use lumbar drain to drain CSF in order to give time to the heal the small defect and medications to decrease the intracranial pressure. Bed rest is advised in almost all the patients. In literature successful outcome is noted over 90% in patients treated with endoscopic approach.⁷

In endoscopic repair of CSF leaks some patients may observe mild headache and pain at operative area, but they can be treated with analgesics easily. Immediately after the surgery NSAIDS like aspirin and ibuprofen should be avoided to minimize the risks of bleeding.⁸ Many patients feel nasal congestion and minor nasal

bleeding after 2-3 weeks of the procedure. These side effects can be overcome by advising patients to keep the head elevated. Most of the surgeons use nasal sprays and sinus rinse kits in order to reduce congestion, remove debris and to keep sinuses moisten. Most of the patients are allowed for walking and light activities while they are restrained to wait for one week for their normal routine activities and return to their office. Most of the consultants advise their patients to avoid weight lifting, blowing from nose, coughing and constipation.

MATERIAL AND METHODS

Study Design and Setting

A comparative, experimental randomized trial was conducted at the Department of Neurosurgery, Lahore General Hospital, Lahore, for 12 months after approval from Ethical Committee.

Sample Size and Sampling Technique

A non-probability and purposive sampling was considered. 40 patients of CSF leak have been divided into two groups of 20 patients each. Keeping the power of study equal to 80%, the sample size was calculated by following formula. The sample size will be 20 in each group of patients. (Sample Size calculation in clinical research by Shien-Chung Chow formula et al. 2005).⁹

$$n = \frac{Z_{\beta}^2 [p_1(1-p_1) + p_2(1-p_2)]}{(p_2-p_1)^2}$$

Where, p_1 is the anticipated proportions like post op complication in endoscopic group = 0.00%.

p_2 is the anticipated proportions of post op complications in trans-cranial group = 3.80%.

$p_1 - p_2$ is the difference between two proportions = 3.80%.

Z_{β}^2 will be the desired power of study = 80%.

Sample Selection

A randomization Balloting method was used. Treatment has been assigned to patients randomly selected by the balloting method after taking consent.

Inclusion Criteria

Both male and female with ages between of 18 to 60 years were included. The patients included who were with persistent CSF leak, having traumatic & spontaneous or iatrogenic CSF leak. Also, those patients included who were with post traumatic CSF leak after failure of conservative treatment for 4 to 6 weeks.

Exclusion Criteria

Sever patients with multiple comorbidities like chronic renal failure and chronic liver disease and patients with active neurological diseases like wound infection and meningitis were not included in this study.

Surgical Procedures

Endoscopic Approach

Systemic antibiotics were given to the patients. Patients were operated in general anesthesia. The head was slightly tilted towards the right side (the side of the operating surgeon). The face and nasal cavity were washed with soap and Betadine solution. A universal endoscope was used (outer diameter of the operating sheath, 6.5 mm; 0-degree telescope). For visual control and instructional purposes, a TV monitor and camera were connected to the endoscope. Adrenaline in saline-soaked cottonoids were left for hemostasis within 3 to 5 minutes before the operating sheath was inserted into the nasal passage. Under direct visualization, the working sheath and telescope were inserted. The mucosal injury was avoided.

By diagnostic endoscopy, the fistula was localized. Leakage sites were recognized in eight

patients as a pulsating, glistening white arachnoid pouch or in twelve patients as CSF leakage via a dural rent, supporting the MRI findings. To validate the leak via the defect in cases of confusion, a Valsalva maneuver was performed.

Depending on the leakage site, the working sheath's location changed slightly, as needed. To increase visualization and intraoperative maneuver ability, the superior turbinate was partly resected. By extracting any granulation tissue or bone chips, the margin of the defect was prepared and harvested accordingly. By the introduction of unipolar coagulation, hemostasis has been accomplished. To clear the surgical area and telescope mirror, intermittent saline irrigation was used through a fine catheter in the working canal. A fascia lata graft of an acceptable size (slightly larger than the defect) was made.

The graft was placed and anchored. Than telescope and other instruments were removed from the operating sheath. In order to direct the graft into the tip of the operating sheath, the telescope was reintroduced. The graft, protected by forceps, was insinuated a few millimeters into the defect, to plug it. By slightly turning them, the holding forceps were removed slowly and the graft was left in place. This was supported by Gelfoam. The posterior nasal packing was accompanied by the removal of the operating sheath.

Post-operatively, with their heads elevated 30 degrees, patients were limited to bed rest. For 3 to 5 days, the intermittent lumbar drainage of CSF was performed twice a day. The nasal packaging was removed 48 to 72 hours after the operation. Sneezing and coughing was avoided in the post-operative period.

Transcranial Approach

The type of the transcranial approach used for CSF leak closure depends on the site of the fistula and the fracture type and size. Several surgical procedures have been identified in the literature,

ranging from the classic frontal craniotomy to the suprasinus transfrontal approach with lateral extension, which may be bilateral or unilateral. Dural replacements, such as pericranial graft, fascia lata, temporalis muscle fascia, or other autologous (preferably) or nonautologous grafts, can be used if the primary reconstruction of the dura is not feasible. The type of technique used to repair the leak depends on the actual scenario and cannot be standardized in an algorithmic manner. Each fracture associated with a CSF leak is special. About the use of graft materials, the same may be said. The choice of graft material depends on the defect's site and length, dural laceration extent, and graft availability. Until the superiority of one surgical technique over another and one form of graft over another is tested by clinical trials, the decision will depend on the condition and the choice of the surgeon.¹⁰

Data Analysis Procedure

The data was collected through a predesigned proforma/questionnaire. By using SPSS 23, the data was entered and analyzed. In the form of Mean \pm SD, numerical information such as age and length of hospital stay was provided. And in the form of frequencies and percentages, qualitative information such as gender, CSF leak and wound infection was provided.

With the student t-test, the numerical data satisfying the parametric assumption was analyzed. Using the Chi Square test, qualitative

data was analyzed. The p-value was considered significant at less than or equal to 0.05.

RESULTS

In this study, 40 subjects were studied for 12 months after treatment, 20 subjects were treated with endoscopic approach for CSF leak repair and 20 were treated with Transcranial surgery for CSF leak repair. Overall success rate was 92.5% and recurrence rate was 7.5%.

Demographics

The mean ages of patients with CSF leak were 25.58 ± 14.38 years. Among the patients, 17 were females and 23 were male. The mean age of the female was 31.70 ± 14.29 years. The mean age of the male was 21.04 ± 12.95 .

Statistical Analysis

The mean age of male and female was statistically significantly different in the endoscopic group where as in trans-cranial group the age was not statistically significant (Table 1). Male female ratio was approximately same in both treatment groups (p-value 0.749) (Table 2).

Recurrence was not found associated with the gender (p-value 0.197) (Table 3). Recurrence rate was not significantly different among both groups (p-value 0.605) (Table 5). There was no association between treatment and infection (p-value 1.00) (Table 6).

Table 1: Comparison of age according to gender and treatment.

Treatment	Sex	N	Mean Age	Std. Deviation	Std. Error Mean	p-value
Endoscopic	Male	12	20.08	13.77	3.97	0.004
	Female	8	38.25	8.73	3.09	
Trans cranial	Male	11	22.09	12.58	3.79	0.561
	Female	9	25.89	16.15	5.38	

Table 2: Comparison according to Sex & Treatment.

Sex	Treatment		Total
	Endoscopic	Tran cranial	
Female	8 47.10%	9 52.90%	17 100.00%
Male	12 52.20%	11 47.80%	23 100.00%
Total	20 50.00%	20 50.00%	40 100.00%

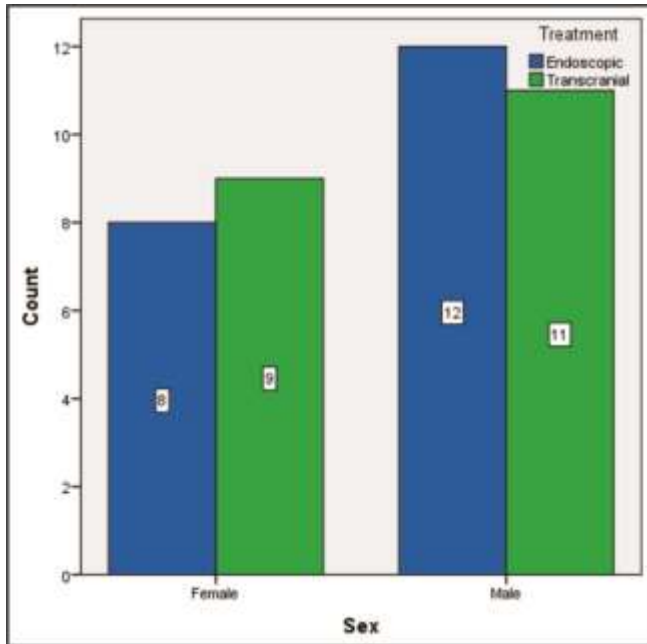


Figure 1: Graphical Representation of Comparison according to Sex & Treatment.

Table 3: Comparison according to Sex & Recurrence.

Sex	Recurrence		Total
	No	Yes	
Female	15 88.23%	2 11.76%	17 100.00%
Male	22 95.70%	1 4.30%	23 100.00%
Total	37 92.50%	3 7.50%	40 100.00%

Table 4: Comparison according to Sex & Infection.

Sex	Infection		Total
	No	Yes	
Female	17 100.00%	0 0.00%	17 100.00%

Male	22 95.70%	1 4.30%	23 100.00%
Total	39 97.50%	1 2.50%	40 100.00%

Infection was not associated with the gender (p-value 1.00) (Table 4).

Table 5: Comparison according to treatment & Recurrence.

Treatment	Recurrence		Total
	No	Yes	
Endoscopic	18 90.00%	2 10.00%	20 100.00%
Trans-cranial	19 95.00%	1 5.00%	20 100.00%
Total	37 92.50%	3 7.50%	40 100.00%

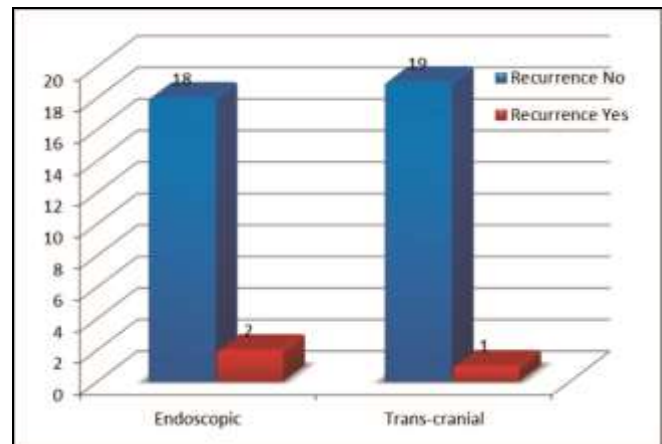


Figure 2: Graphical representation of Comparison according to treatment & Recurrence.

Table 6: Comparison according to treatment & Infection.

Treatment	Infection		Total
	No	Yes	
Endoscopic	20 100.00%	0 0.00%	20 100.00%
Trans-cranial	19 95.00%	1 5.00%	20 100.00%
Total	39 97.50%	1 2.50%	40 100.00%

DISCUSSION

Cerebro-spinal Fluid (CSF) Rhinorrhea usually known as CSF Leak can be divided into traumatic and non-traumatic. Traumatic CSF Leak commonly arises from frontal or ethmoid sinuses through cribriform plate or from petrous part of temporal bone through the eustachian tube up to the nasopharynx. Iatrogenic injuries may be caused by trauma or fiddling during surgery or due to external injuries which could be penetrated or blunt either at anterior cranial fossa or posterior cranial fossa. Non-traumatic causes lead to direct injury or rapidly increasing in ICP because of intracranial tumors, congenital or acquired hydrocephalus, or infections like osteomyelitis and tuberculosis.

With advent of modern surgical procedures for endoscopic repair of CSF fistula, the cases have been markedly decreased for spontaneous leaks. Most of the surgeons still prefer the conservative management as the first line management for cases of spontaneous CSF rhinorrhea. This includes complete bed rest in pro-up position at 45 degrees for 1 to 2 weeks along with laxatives and antitussive drugs. Role of use of antibiotics is controversial if there is no any infection. Lumbar drain is used for 4 to 7 days in those which do not respond on conservative treatment. Surgery is the last option in patients, which fails on conservative management or having persistent CSF leaks. Patients with open meningoceles and meningoencephaloceles especially with infection or meningitis usually need surgical repair.

In 1995, Anand and his team¹¹ published their outcomes with endoscopic repair of CSF leak. Out of twelve patients, 11 (92%) were repaired successfully in 1st procedure. They passed lumbar drain in all the patients for 4 to 7 days. In 1996 Lanza and his team reported that out of 36 patients 34 (94%) patients repaired successfully in 1st attempt.⁶ They passed lumbar drain in 28 patients immediately after the surgery. Lumbar

drain was kept for 2-5 days. In 1996 Burns and his co-workers reported their results out of 42 patients 35 (83%) patients underwent successful repair of CSF leak in 1st attempt remaining 7 patients successfully repaired in 2nd attempt. Success rate was 90% in their study. Lumbar drain was not inserted in any of the patient. These patients has average hospital stay of 3 days.¹²

In 1997 Hughes and his associates reported their results in 17 patients. Sixteen (94%) patients were successfully repaired in 1st attempt. They never used lumbar drain in any of the patient.¹³ Casiano has reported that 33 patients underwent successful endoscopic repair of CSF leaks without a lumbar drain. All the patients with tear less than 5 mm were repaired successfully without any post-operative complication. The patients having CSF leak less than 3 cm had success rate of 95% in 1st attempt.¹⁴

CSF leak is the commonest cause of bed occupancy in the neurosurgery wards.¹⁵ In Pakistan, as it is developing country, the public sector hospitals are over burden like in Karachi and Lahore. Hospital stay is very short in patient who underwent in endoscopic repair of CSF leak like 4-5 days and it is prolonged in trans-cranial approach like 7 days (till the stitches are removed). The duration of procedure is very short in endoscopic repair like around 2 hours and it is prolonged in Trans-cranial approach around 4-5 hours. Therefore this study was conducted to determine that the outcomes are same in endoscopic repair as compared to trans-cranial repair.

There are many surgical procedures to treat skull base CSF leaks. Starting from conservative management like bed rest and avoidance of things which increases intra-abdominal pressure so the ICP are weight lifting, coughing, constipation and pregnancy. CSF diversion procedures like serial lumbar punctures, lumbar drains and VP shunts can also be used. If patient is not responding to these measures than we have surgical procedures. Surgical intervention to

repair CSF leak is through trans-cranially by frontal/bi-frontal craniotomy or trans-sphenoidal endoscopic approach under direct visualization. Study shows that endoscopic repair of CSF leaks has good outcome than others because of direct visualization and minimal complication rate.¹⁶

Accurate preoperative identification of the site of the CSF leak, its size, and the anatomy of the surrounding region is the key to the endoscopic surgical repair of CSF rhinorrhea. For preoperative localization of the defect, HRCT, MRI, radioisotope cisternography, CT cisternography, and MR cisternography are all helpful. The most commonly used are HRCT and MRI.¹⁷

Indication of Endoscopic Repair of CSF Rhinorrhoea: Cribriform, ethmoid, sphenoid, and frontal sinus defects smaller than 1.5 cm in size, most of which are easily assessable transnasally, are ideally treated by transnasal endoscopic technique. However, defects less suitable for endoscopic repair are: defects greater than 1.5 cm, lateral extension frontal sinus defects and frontal sinus posterior wall defects.

Persistent CSF rhinorrhea which needed 2nd endoscopic repair is around 5-10%. Success rate in these patients is 97%. Endoscopic repair is the procedure of choice for patients having CSF leak smaller than 1.5 cm in cribriform, ethmoid, and sphenoid sinus. Endoscopic repair has less morbidity, a minimum complication rate and overall a much higher success rate as compared to open surgical methods. However an open approach may still be needed for defects higher than 1.5 cm in size and in unfavorable areas (posterior frontal sinus wall, etc.).¹⁸

A large series of 29 cases with 76 percent success with 1st endoscopic procedure and 86 percent success with 2nd procedures were recorded by Dodson and his associates.¹⁹ Four patients eventually had neurosurgical intervention for recurrence of CSF rhinorrhea. There were no lumbar spinal drains used. Kelley and his friend published 8 patients who underwent transsphenoidal excision of pituitary tumor

developed CSF leakage. Out of them 7 patients (88 percent) were successfully treated with 1st attempt, while only 1 patient was repaired in 2nd attempt.²⁰

Stammberger et al²¹ had recorded a success rate of 94.5 percent with a single endoscopic procedure in 41 patients with CSF rhinorrhea, the largest study to date documenting the outcomes of endoscopic repair. Furthermore, an estimated number of 128 endoscopic encephalocele repair cases have been reported. With an estimated 93 percent success with one attempt and 97 percent success with a second attempt, the success rates were very close. The average occurrence of complications was 9.4 percent higher than leak repair, although the magnitude of complication also seems higher, possibly due to the direct fiddling needed for encephalocele repair of neurological tissue. No problems with long-term sequelae, however have been A well-known complication following reconstruction of ventral and anterior skull base dural defects is CSF leakage. Reconstruction with vascularized tissue is much desirable for quicker healing especially when the patient has been irradiated. Hadad and Bassagasteguy introduced the use of pedicle flap from nasal septum. The vascular supply is from nasoseptal artery.²²

The fact that the HBF flexibility, durability, arc of rotation, and area of coverage is superior to any other flap previously mentioned is responsible for this rich vascular pedicle and branching. As demonstrated by the identical findings obtained by our two separate teams in two distinct institutions and by other anecdotal results, the results are highly reproducible. The HBF has the potential to become the working horse for the reconstruction of the skull base's large defects and adds a high level of reliability to the existing reconstruction methods. The only caveat is that before a posterior septectomy is carried out, it has to be expected in advance, since this will damage the vascular pedicle.²²

Factors linked to the possible failure of an

endoscopic approach include the following: inability to identify the bone defect; displacement of the graft; inadequate length of the graft; incomplete application of the graft to the bone defect of the skull; failure of the patient to comply with postoperative instructions; and lastly slow healing of the wound. It is extremely necessary that the graft fixed completely with the receiver bed and that the defect is not tented or stretched. Management of CSF leaks was reported to have a failure rate of 20 percent to 40 percent via an intracranial approach.

Mattox and Kennedy were the pioneers of endoscopic repair of CSF leaks and encephaloceles.⁶ Initially 6 out of 7 patients (85.7%) had successful repair later reaching 100% following the second set of patients. Dodson et al published large number of cases of endoscopic repairs. They did 29 cases in the first go, and 22 (75.9%) patients had a complete CSF leak repair. CSF leakage was resolved by this group of surgeons in their 2nd attempt in 25 out of 29 (86.2%) patients. Afterwards, the repairs were good reaching 94.4% in a set of 36 patients, whereas, 34 patients cured. One of the patients had a failed surgery, he was followed up for one and a half month and was finally deemed cured. When the intracranial surgical approaches are compared to extracranial approaches, the success rate is much higher in extracranial approaches with significantly less morbidity.¹⁹

The literature supports the use of free grafts of both flaps since both strategies for repairing CSF leaks have been documented to be highly effective. In just 17 percent of the CSF repairs, a vascularized flap consisting of middle turbinate bone or septal mucoperichondrium with or without cartilage was used. There was no connection between the type of grafting material, the position of the leak, the size of the defect, the type of repair, the perioperative management and the cause of the leak, and the persistence or recurrence of the CSF leakage.

The use of prophylactic antibiotics, the use of

nasal packaging, and diversion of CSF, with either a lumbar drain or VP shunt, were aspects of perioperative management that were checked. Antibiotics were used for an average duration of 4 to 7 days in more than 83 percent of cases. The use of antibiotics in patients with CSF leaks for the prevention of meningitis continues to be controversial because their effectiveness is unproven and resistant bacteria can be chosen. However, for the first 48 hours after surgery, perioperative prophylactic antibiotics during skull base surgery are recommended. In fact, for a period of time, patients with in-dwelling lumbar catheters and/or packing routinely received prophylactic antibiotics associated with that of the packing or drain.

In our study, the recurrence of CSF leak was observed in only 7.5% and overall success rate was 92.5%. In endoscopic approach, two patients were observed with recurrences, which were successfully repaired in a second operation (Table 5 and Figure 2). One patient (2.50%) among the trans-cranial approach develops infection which was treated successfully (Table 4). In few studies, the average hospital stay was 4.3 days¹⁹ and 6.5 days.²³ In our study, average hospital stay was 4 days in endoscopic and 7 days in trans-cranial approach.

CONCLUSION AND RECOMMENDATION

Endoscopic repair has less morbidity, a lower complication rate and a higher overall success rate compared to open surgical methods. It is suggested that endoscopic repair of CSF leak is both safe and effective and in most cases, should be considered as standard procedure of choice.

REFERENCES

1. Deangelis LM. Tumors of the central nervous system and intracranial hypertension and hypotension. Goldman's Cecil Medicine: Elsevier; 2012: p. 1246-57.

2. Warnecke A, Averbek T, Wurster U, Harmening M, Lenarz T, Stöver T. Diagnostic relevance of β 2-transferrin for the detection of cerebrospinal fluid fistulas. *Archives of Otolaryngology-Head & Neck Surgery*, 2004; 130 (10): 1178-84.
3. Roy AK. Book Review: The Greenberg Rapid Review: A Companion to the 8th Edition. Oxford University Press; 2017.
4. Mathias T, Levy J, Fatakia A, McCoul ED. Contemporary Approach to the Diagnosis and Management of Cerebrospinal Fluid Rhinorrhea. *Ochsner J*. 2016; 16 (2): 136-42.
5. Landreneau FE, Mickey B, Coimbra C. Surgical treatment of cerebrospinal fluid fistulae involving lateral extension of the sphenoid sinus. *Neurosurgery*, 1998; 42 (5): 1101-4.
6. Lanza DC, O'Brien DA, Kennedy DW. Endoscopic repair of cerebrospinal fluid fistulae and encephaloceles. *The Laryngoscope*, 1996; 106 (9): 1119-25.
7. Daroff RB, Fenichel GM, Jankovic J, Mazziotta JC. *Neurology in clinical practice*: Elsevier Health Sciences; 2012.
8. Jho H-D, Carrau RL. Endoscopic endonasal transsphenoidal surgery: experience with 50 patients. *Neurosurgical Focus*, 1996; 1 (1): E4.
9. Chow S-C, Chang M, Pong A. Statistical Consideration of Adaptive Methods in Clinical Development. *Journal of biopharmaceutical statistics*, 2005; 15: 575-91.
10. Hegazy HM, Carrau RL, Snyderman CH, Kassam A, Zweig J. Transnasal endoscopic repair of cerebrospinal fluid rhinorrhea: a meta-analysis. *The Laryngoscope*, 2000; 110 (7): 1166-72.
11. Anand VK, Murali RK, Glasgold M. Surgical decisions in the management of cerebrospinal fluid rhinorrhoea. *Rhinology*, 1995; 33 (4): 212.
12. Burns JA, Dodson EE, Gross CW. Transnasal endoscopic repair of cranionasal fistulae: a refined technique with long-term follow-up. *The Laryngoscope*, 1996; 106 (9): 1080-3.
13. Hughes R, Jones N, Robertson I. The endoscopic treatment of cerebrospinal fluid rhinorrhoea: the Nottingham experience. *The Journal of Laryngology & Otology*, 1997; 111 (2): 125-8.
14. Casiano RR, Jassir D. Endoscopic cerebrospinal fluid rhinorrhea repair: is a lumbar drain necessary? *Otolaryngology – Head and Neck Surgery*, 1999; 121 (6): 745-50.
15. smajja ms. To Determine Frequency of Cerebrospinal Fluid (CSF) Rhinorrhoea after Trans-sphenoidal (TSS) Surgery, 2016;. 2016: Epub 2016-04-11.
16. Giovannetti F, Ruggeri A, Buonaccorsi S, Pichierri A, Valentini V. Endoscopic endonasal approaches for cerebrospinal fluid leaks repair. *Journal of Craniofacial Surgery*, 2013; 24 (2): 548-53.
17. Lloyd M, Kimber P, Burrows E. Post-traumatic cerebrospinal fluid rhinorrhoea: modern high-definition computed tomography is all that is required for the effective demonstration of the site of leakage. *Clinical Radiology*, 1994; 49 (2): 100-3.
18. Paul P, Upadhyay K. Endoscopic endonasal repair of traumatic CSF rhinorrhoea. *Indian Journal of Neurotrauma*, 2010; 7 (01): 67-9.
19. Dodson EE, Gross CW, Swerdloff JL, Gustafson LM. Transnasal endoscopic repair of cerebrospinal fluid rhinorrhea and skull base defects: a review of twenty-nine cases. *Otolaryngology — Head and Neck Surgery*, 1994; 111 (5): 600-5.
20. Kelley TF, Stankiewicz JA, Chow JM, Origitano TC, Shea J. Endoscopic closure of postsurgical anterior cranial fossa cerebrospinal fluid leaks. *Neurosurgery*, 1996; 39 (4): 743-6.
21. Tomazic PV, Stammberger H. Spontaneous CSF-leaks and meningoencephaloceles in sphenoid sinus by persisting Sternberg's canal. *Rhinology*, 2009; 47 (4): 369.
22. Hadad G, Bassagasteguy L, Carrau RL, Mataza JC, Kassam A, Snyderman CH, et al. A novel reconstructive technique after endoscopic expanded endonasal approaches: vascular pedicle nasoseptal flap. *The Laryngoscope*, 2006; 116 (10): 1882-6.
23. Sautter NB, Batra PS, Citardi MJ. Endoscopic management of sphenoid sinus cerebrospinal fluid leaks. *Annals of Otology, Rhinology & Laryngology*, 2008; 117 (1): 32-9.

Additional Information

Disclosures: Authors report no conflict of interest.

Ethical Review Board Approval: The study was conformed to the ethical review board requirements.

Human Subjects: Consent was obtained by all patients/participants in this study.

Conflicts of Interest:

In compliance with the ICMJE uniform disclosure form, all authors declare the following:

Financial Relationships: All authors have declared that they have no financial relationships at present or within the previous three years with any organizations that might have an interest in the submitted work.

Other Relationships: All authors have declared that there are no other relationships or activities that could appear to have influenced the submitted work.

AUTHORS CONTRIBUTIONS

Sr.#	Author's Full Name	Intellectual Contribution to Paper in Terms of:
1.	Tarique Salah-ud-Din	Study design and methodology.
2.	Ishfaqe Ahmed Simair	Paper writing, referencing and data calculations.
3.	Amjad Qureshi	Data collection and calculations.
4.	Jawad Ali	Analysis of data and interpretation of results etc.
5.	Abid Khattak	Literature review and manuscript writing.
6.	Mian Awais	Analysis of data and quality insurer.